

Volumetric techniques: three-dimensional midface modeling

Arleta Macierzyńska¹, Ewa Pierzchała¹, Waldemar Placek²

¹Institute of Aesthetic Medicine, Department of Cosmetology, Medical University of Silesia, Katowice, Poland

Head of the Department: Ewa Pierzchała MD, PhD

²Department and Clinic of Dermatology, Sexually Transmitted Diseases and Clinical Immunology, University of Warmia and Masuria, Olsztyn, Poland

Head of the Department: Prof. Waldemar Placek MD, PhD

Postępy Dermatologii i Alergologii 2014; XXXI, 6: 388–391

DOI: 10.5114/pdia.2014.40981

Abstract

Aging is a complex process caused by many factors. The most important factors include exposure to UV radiation, smoking, facial muscle movement, gravity, loss and displacement of fat and bone resorption. As a symptom of aging, face loses elasticity, volume and cheerful look. While changing face proportions, the dominant part of a face is its bottom instead of the mid part. The use of three-dimensional face modelling techniques, particularly the mid-face – tear through and cheeks, restores the skin firmness, volume and healthy look. For this purpose the hyaluronic acid is used, calcium hydroxyapatite, and L-poly-lactic acid fillers. Volumetric techniques require precision and proper selection of the filling agent to give a sense of satisfaction to both the patient and the doctor.

Key words: hyaluronic acid, calcium hydroxyapatite, L-poly-lactic acid.

The ageing of the skin

The ageing process is multifactorial and complex. One of the most important factors is skin damage caused by prolonged exposure to UV radiation. The ageing process comprises a loss of fullness of the face characteristic of young people. It results from the loss of subcutaneous tissue, which leads to flattening of the facial structures. Changes in facial muscles are not neutral, either. Facial muscles insertions are located directly in the skin. Many years of work involving these muscles leads to the formation of dynamic wrinkles. Initially, they appear only in the period of increased mimic activity, then wrinkles become durable and are visible at rest. Dynamic wrinkles occur in the areas where facial muscles and fascia are directly linked to the skin. This is within the forehead, glabellar area, nasolabial area, around the mouth and eyes. Gravitation changes are caused by the loss of tissue elasticity. During the ageing process, facial soft tissue loses its innate resilience and stretch resistance. Inevitably, the influence of gravity causes tissue sagging. Over the years, a process of bone resorption also takes place. It may lead to a visible reduction in the volume of the face. The force

of gravity extends cartilage structures, leading to their sagging, which can be seen for example in relation to the tip of the nose. Hormonal changes also lead to decreased skin elasticity. The way of life is also important: healthy diet, getting enough sleep, smoking. However, in recent years the main role has been attributed to the processes of bone resorption and fat redistribution [1–4]. Change to eating habits and regulation of hormonal changes can slow down the ageing process [5].

Young face

The face of young people is full and rounded, especially in the upper and middle parts. A face like this is found healthy, shiny and full of energy. During the ageing process in this area, tissues lose volume, the excess of cheek skin occurs and it starts to dominate in the lower part of the face. Very often the face is perceived as sad, heavy, long, weary and ashen. Often, by evaluating the appearance, person's disposition is also evaluated in the same manner [1, 2, 6].

Address for correspondence: Arleta Macierzyńska MD, Institute of Aesthetic Medicine, Department of Cosmetology, Medical University of Silesia, 20/24 Francuska St, 40-027 Katowice, Poland, phone: +48 668 266 990, e-mail: arleta.macierzynska@gmail.com

Received: 10.10.2013, **accepted:** 25.01.2014.

Two-dimensional and three-dimensional face modelling

Before volumetric techniques popularization, fillers' use was limited to smoothing skin surface – filling lines and wrinkles. The result was to improve the tension and structure of the skin. Modelling like this is referred to as two-dimensional, because it does not affect the contour of facial structures, and does not solve the problem of tissue volume loss in the upper and middle parts of the face, and the skin excess in the lower part of the face. The development of volumetric techniques allows for three-dimensional modelling, through reconstruction of volume loss associated with changes in the soft tissue and bone structures. Tissue augmentation within the tear trough and cheeks restores face's young and healthy appearance, the light reflects otherwise from the face, giving the impression of freshness. In addition, cheeks' volume restoration reduces skin sagging in the lower part of the face and also reduces the nasolabial folds [1, 6] (Figures 1 and 2).

The “ideal” filler

The aesthetic medicine market offers many substances that add volume to soft tissues. The use of these substances for years has allowed for the creation of the characteristics of an “ideal” filler: adding volume, easy in use, giving an opportunity to shape the tissues, reversible results, average life, safe use, giving satisfaction to the patient and the physician, giving a natural effect, not causing patient's discomfort, requiring no time recovery, predictable, not giving allergic reactions and irritation [1].

For reasons of cost and patient comfort, a filler should have a good durability. However, it is known that the face topography changes over time. The use of the permanent fillers result in an unnatural face appearance, because it will not undergo changes, in contrast to the surrounding tissue [1]. Soft tissue fillers work using two main mechanisms: the filler material occupies space in the tissue and stimulates fibroblasts to synthesize collagen, resulting in tissue volume [2].

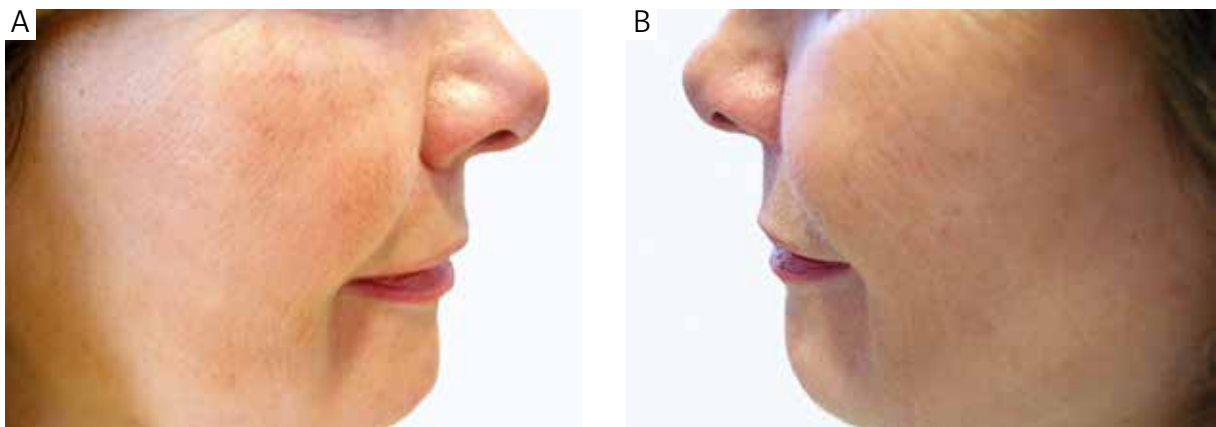


Figure 1. Before volumetry treatment

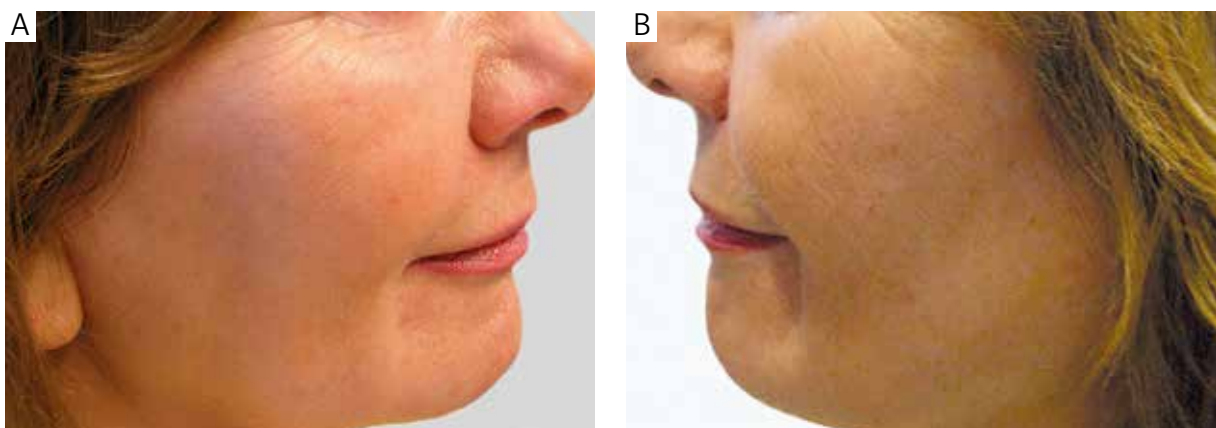

Figure 2. After volumetry treatment

Hyaluronic acid

Hyaluronic acid (hyaluronate, sodium hyaluronate, HA) is a naturally occurring glycosaminoglycan having a linear structure, composed of fragments of polysaccharides of D-glucuronic acid and N-acetyl-D-glucosamine arranged alternately. It is widespread in the extracellular matrix of connective tissue, synovial fluid, vitreous and aqueous of the eyeball and in some other tissues. It shows no species or tissue specificity in contrast to collagen. Its chemical structure is uniform throughout nature, and therefore in its pure form is devoid of potential immunogenic properties. In the skin, a tissue matrix is created that has viscoelastic properties, in which there are embedded collagen and elastic fibres and other extracellular structure. This feature allows to create volume, consistency and skin elasticity. The hyaluronic acid has a high molecular weight (50 kDa), connects a large amount of water (1 molecule is able to join a weight of 1,000 times larger than itself). The content of hyaluronic acid in the skin decreases with age, leading to its dehydration and wrinkle occurrence. Due to its stabilizing, hydrating and cushioning properties and high biocompatibility, it is an ideal material for soft tissue filling. The process of filling requires presence of the filler in the place of its deposit. Half-life of hyaluronic acid in tissue of only 1–2 days (exogenous hyaluronic acid is rapidly eliminated from the dermis and degraded in the liver to carbon dioxide and water), the unmodified substance poorly meets the requirements of filling preparations. For longer life preparations, the crosslinking process is carried out. The result is more stable macromolecules which have the same hyaluronic acid biocompatibility, but are insoluble in water. Because of this property, they are maintained in tissues over a period of time after an injection. The degree of crosslinking determines the durability and biocompatibility of the formulation. After the crosslinking process, hyaluronic acid retains its affinity for water, increases volume, creating a three-dimensional network defined as a gel. Fillers in a tissue remain stable, undergoing a slow resorption process for months, which can be carried by isovolemic degradation formula: while degradation of individual molecules of hyaluronic acid, the remaining ones bind larger amounts of water, causing the total volume of the residual gel not to get changed. The concentration of the gel is reduced during its resorption, but the volume remains high until the last molecules of hyaluronic acid are not subject to degradation. Depending on the concentration and cross-linking, the hyaluronic acid fillers can be applied to the superficial layers of the dermis, to the middle layers of the dermis, to the lower layers of the dermis, and subcutaneous [2, 7]. The authors report that the effect of correction of hyaluronic acid is maintained for about 12 to 18 months [2, 7, 8]. However, in the study published by Callan *et al.*,

the effect of volumetric middle face was maintained for up to 24 months [9].

Calcium hydroxyapatite – Radiesse®

It is a naturally occurring mineral in teeth and bones. It is used in plastic surgery of the larynx, cranial maxillofacial defects, vocal cord augmentation and urology to treat urinary incontinence. It was also used in radiological imaging techniques, because of the impermeability of the X-ray. Calcium hydroxyapatite is a matrix present within the bone and other tissues. The product that undergoes the bioengineering procedures serves as a natural scaffold for cells including osteoblasts, fibroblasts, allowing to carry out semi-permanent treatments of soft tissue correction. The product has a gel carrier comprised of water, glycerol, carboxymethyl cellulose and matrix molecules-granules with a 25–45 µm in diameter. Before using this preparation, any allergy test is required, since the components do not exhibit any allergic or toxic properties. Molecular structure of calcium hydroxyapatite is identical to the structure forming a “scaffold” of human bones. Distribution of the product within the middle or the superficial dermis (especially in patients with a fair or thin skin) will cause the material to be visible through the skin. When injected into the subcutaneous tissue, a matrix gel is absorbed. Cells from the surrounding tissues that grow into the scaffolding of filler biomatrix begin to produce their own material. Thus, if the filler is injected into the subperiosteal space, it starts the stimulation of producing the bone tissue. If the preparation is injected into soft tissue, it stimulates the production of collagen by fibroblasts. Placing the filler out of reach of fibroblasts will mean a lack of collagen deposition or will stimulate its inception in the wrong location. The filling effect lasts for 18–24 months [7].

L-polylactic acid – Sculptra®

Is a synthetic biodegradable and bioresorbable polymer. As a filler it is used in the areas of high loss of tissue volume, but is not suitable for filling individual wrinkles. It can be used in combination with other fillers. In 2004, it was approved for patients with HIV and facial lipoatrophy. It comes in the form of lyophilized powder, to be dissolved before use with 5 ml of water with anesthetics. The minimum time from dissolution to the administration of the product is 2 h, but the longer time – 12–24 h of hydration can reduce clogging of the needle and the problem of granulation of the product. It is injected in 0.1–0.2 ml deposits at the subcutaneous level or into the muscle. Elevation of the tissue after L-polylactic acid administration appears after weeks or months, due to an increase in the amount of collagen type I in the areas where deposits of L-polylactic acid are absorbed. The volumetric effect is maintained for 2 to 3 years. Mostly, the

therapy is carried out in a series of 3–4 treatments at intervals of 4–6 weeks [2, 7].

The filler selection

Restoring cheeks and tear through volume is a very good way to give the face a young, healthy and radiant appearance [6]. The authors often combine different types of fillers to get an ideal effect. Freid recommends filling the tear through with hyaluronic acid, but cheeks with preparations of L-poly-lactic acid or calcium hydroxyapatite [6]. Greco *et al.* recommend a similar solution, but for filling cheeks they also use hyaluronic acid [7]. Funt uses hyaluronic acid and calcium hydroxyapatite to fill these two areas. Braz and Sakuma use the most cross-linked hyaluronic acid for cheeks volumetry [10].

Possible complications and how to avoid them

Although volumetric techniques help to restore youthful, fresh appearance and facial harmony, their use is associated with some complications like bruising, erythema, pain, infection, skin necrosis, the effect of over-correction, infraorbital nerve damage, visible material – Tyndall effect. There may also be lumps, nodules and malar oedema. These complications can occur irrespective of the filler material. A particularly strong side effect is malar oedema occurring during the cheek injection within the tear through. Duration of oedema can be up to 8 months, in addition to this, oedema does not respond to standard procedures (massage, prednisolone injections, corticosteroids, taping). Procedures that prevent malar oedema formation are the right filler choice, small doses of filler administration, and placing filler material deep into the malar septum [11].

Summary

Three-dimensional volumetric techniques of the midface are a great way to get a younger and more radiant appearance. The market offers filler substances with a high safety profile. A carefully selected preparation or their combination, and a safe application technique will result in the satisfaction for both the patient and the doctor.

References

1. Muhn C, Rosen N, Solish N, et al. The evolving role of hyaluronic acid fillers for facial volume restoration and contouring: a Canadian overview. *Clin Cosmet Investig Dermatol* 2012; 5: 147-58.
2. Burges CM. Principles of soft tissue augmentation for the aging face. *Clin Investig Aging* 2006; 1: 49-55.
3. Mendelson B, Wong CH. Changes in the facial skeleton with aging: implications and clinical applications in facial rejuvenation. *Aesth Plast Surg* 2012; 36: 753-60.
4. Espinoza GM, Holds JB. Evaluation and treatment of the tear trough deformity in lower blepharoplasty. *Semin Plast Surg* 2007; 21: 57-64.
5. Goodman GJ, Roberts S. "Home of Younger Skin" (HOYS) program: defining the change in apparent skin age after facial treatment with botulinum toxin and dermal fillers. *Clin Cosmet Investig Dermatol* 2012; 5: 93-9.
6. Freid RG. Filler cheeks: a bright idea? The "eyes" have it. *J Clin Aesthet Dermatol* 2011; 4: 44-7.
7. Greco TM, Antunes MB, Yellin SA. Injectable fillers for volume replacement in the aging face. *Facial Plast Surg* 2012; 28: 8-20.
8. Hoffman K. Volumizing effects of a smooth, highly cohesive, viscous 20 mg/ml hyaluronic acid volumizing filler: prospective European study. *BMC Dermatol* 2009; 9: 9.
9. Callan P, Goodman GJ, Carlisle I, et al. Efficacy and safety of hyaluronic acid filler in subjects treated for correction of midface volume deficiency: a 24 month study. *Clin Cosmet Investig Dermatol* 2013; 6: 81-9.
10. Braz AV, Sakuma TH. Midface rejuvenation: an innovative technique to restore cheek volume. *Dermatol Surg* 2012; 38: 118-20.
11. Funt DK. Avoiding malar edema during midface/cheek augmentation with dermal fillers. *J Clin Aesthet Dermatol* 2011; 4: 32-6.